



## PATIENT

Bayi Gong

## SPECIES

Feline

## BREED

DSH

## SEX

MN

## AGE

7 y

## WEIGHT

8.2 lb

## INTERPRETED BY

Keith Blass, DVM, MS,  
DACVIM (Cardiology)

## IMAGING PERFORMED BY

Graham Sager-  
Gellerman, DVM

## HOSPITAL NAME

Back Bay VC

## REFERRING VET

Dr. Chapman

## INVOICE

## DATE

12/12/25

## PRESENTING CLINICAL SIGNS

BNP 112. Pre-anesthetic evaluation (COHAT).

## ECHOCARDIOGRAPHIC FINDINGS

2D, M-mode, and Doppler study.

Left atrial size is normal. The mitral valve appears normal, though trace mitral regurgitation is present. Left ventricular wall thickness is normal. Left ventricular internal dimensions are normal. Left ventricular systolic function is normal. The aorta and aortic valve are normal. Right atrial and right ventricular dimensions are normal. The tricuspid valve appears normal, though mild tricuspid regurgitation is present. TR velocity is borderline for the presence of mild pulmonary hypertension. The pulmonary artery and pulmonic valve are normal. No shunting lesions are visualized. No pericardial effusion or cardiac masses are seen.

ECG during echo: Sinus rhythm

LA/Ao – 1.33

IVSd – 4.2 mm

LVPWd – 4.2 mm

LVIDd – 11.1 mm

LVIDs – 5.4 mm

FS – 51.4%

RA – 8.7 mm

LVOT – 0.73 m/s

RVOT – 1.34 m/s

TR – 2.80 m/s

## ASSESSMENT/RECOMMENDATIONS

This examination demonstrates mild regurgitation of blood across Bayi's tricuspid valve. The hemodynamic effects of the regurgitation also appear to be mild, as Bayi does not have secondary dilation of either of his right heart chambers. As such, Bayi's current risk for the development of right-sided congestive heart failure appears to be low.

Bayi's cardiovascular risk for general anesthesia appears to be low based on this exam, though I still recommend avoiding the use of alpha-2 agonists in the anesthetic protocol and reducing the IV fluid rate by 25% as precautions. If possible, monitoring of heart rhythm, blood pressure, and pulse oximetry are recommended during the procedure.

A recheck echocardiogram is recommended in 6 months.



### PATIENT

Bayi Gong

### SPECIES

Feline

### BREED

DSH

### SEX

MN

### AGE

7 y

### WEIGHT

8.2 lb

### INTERPRETED BY

Keith Blass, DVM, MS,  
DACVIM (Cardiology)

### IMAGING PERFORMED BY

Graham Sager-Gellerman, DVM

### HOSPITAL NAME

Back Bay VC

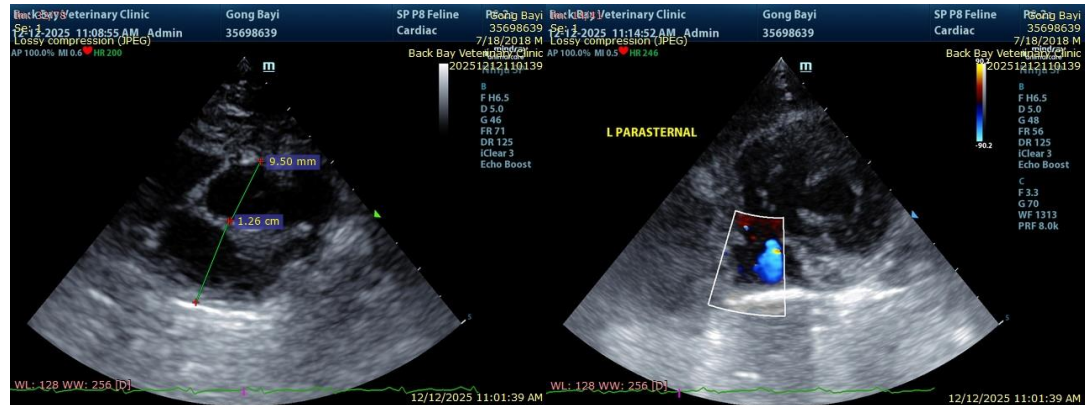
### REFERRING VET

Dr. Chapman

### INVOICE

### DATE

12/12/25



The information and recommendations provided are based on the images presented by the referring veterinarian/sonographer. No evaluation can be communicated regarding pathology that was not visible in the image/video clips provided.

Thank you for this referral. If the clinical or image interpretation does not parallel your findings or if I can be of any further assistance please contact me.

Keith Blass, DVM, MS, DACVIM (Cardiology)

[info@SonoPath.com](mailto:info@SonoPath.com)